



# **Corticosteroid Injection of TMJ Arthritis in JIA**

**Randy Q. Cron, MD, PhD**

**The Children's Hospital of Philadelphia/  
University of Pennsylvania**

**ARHP, San Antonio, TX  
October 2004**



## **TMJ Arthritis in JIA (outline of talk)**

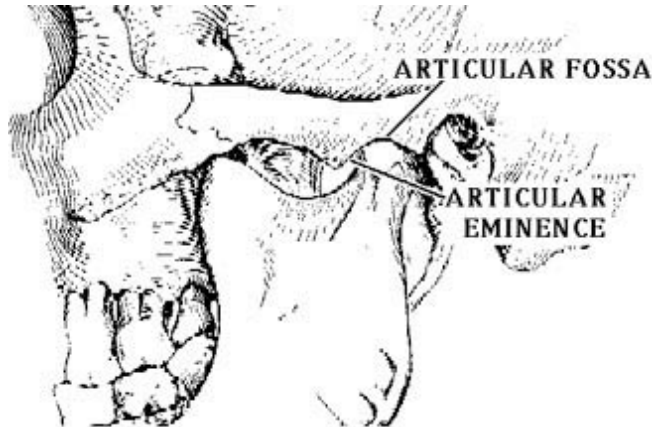
- Review
  - Definition/anatomy
  - Diagnosis
  - Prevalence/incidence
  - Morbidity
  - Treatment
- What's New
  - Retrospective steroid injection study
  - Future studies

## What is the Temporomandibular Joint?

The temporomandibular joint (TMJ) is a typical sliding "ball and socket" which has a disc sandwiched between it. The TMJ is used many hundreds of times a day in moving the jaw, biting and chewing, talking and yawning. It is one of the most frequently used of all the joints in the body.

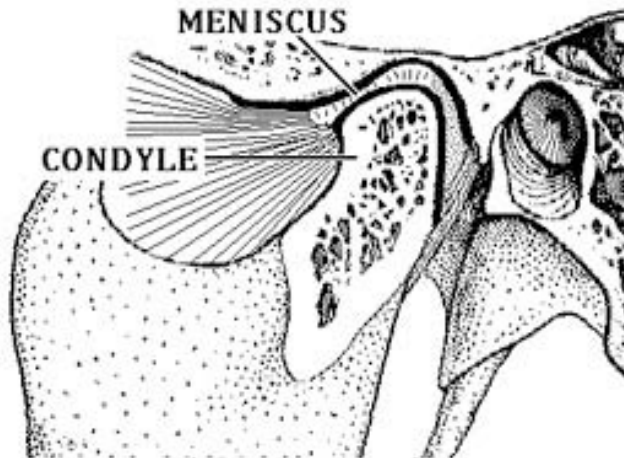
- [http://www.medicinenet.com/temporomandibular\\_joint\\_disorder/page1.htm#1whatis](http://www.medicinenet.com/temporomandibular_joint_disorder/page1.htm#1whatis)

## Bone Anatomy of TMJ



<http://www.rad.washington.edu/anatomy/modules/TMJ/TMJMR.html>

## Parasagittal Image of TMJ




<http://www.rad.washington.edu/anatomy/modules/TMJ/TMJMR.html>

## TMJ Cartilage

- TMJ cartilage, a secondary cartilage with developmental differences from limb cartilages, as reflected in its responsiveness to growth factors and hormones and its extracellular matrix composition. Joint contains both fibrocartilage and hyaline cartilage.

## Challenges in Assessing Pediatric TMJ disease



## Asymptomatic TMJ Disease in JIA

- Twilt et al. 2004
  - 45% without pain
- Wallace et al. 2000
  - 70% asymptomatic



## Diagnosis of TMJ Arthritis in JIA

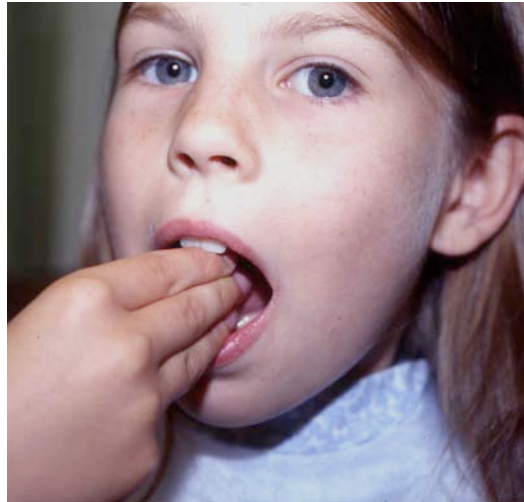- By history: pain, stiffness, dysfunction
- By exam: micrognathia, laterality, tenderness, crepitus, clicking
- By imaging:
  - X-ray (panoramic view, orthopantomogram)
  - CT
  - Ultrasound
  - MRI



## Twilt et al. (Leiden) TMJ involvement in JIA. J. Rheumatol. 2004;31:1418

- 97 consecutive patients with JIA evaluated by orthodontic exam and orthopantomogram.
- Noted by patients with TMJ involvement (**45%**):
  - Pain 55%      Pain with jaw excursion 67%
  - A.M. stiffness 50%      Swelling 80%
  - Clicking 67%      Crepitation 67%
- Orthodontic exam:
  - Asymmetric opening 71%      Clicking 69%
  - Absence of translation 73%      Crepitation 88%

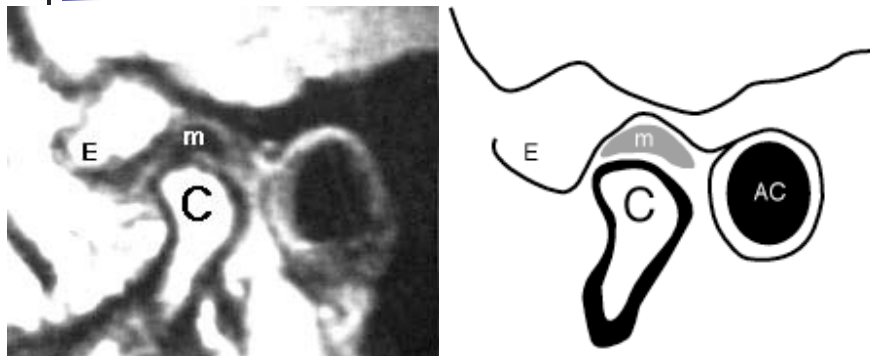
## Tooth-to-tooth Gap/ Interincisor Distance



## Mouth Opening by Age Twilt et al. 2004

Age (yrs):	0-6	6-11	11-16	16-21
Ingervall 1970		49 mm		51 mm
Sheppard 1965	42 mm	46 mm	51 mm	49 mm
+ OPG 2004	43 mm	48 mm	53 mm	53 mm
- OPG 2004	42 mm	43 mm	47 mm	57 mm

## MRI Parasagittal Image of TMJ



*normal TMJ MR showing normal meniscus (m) posterior and superior to condyle (C) -- the articular eminence (E) and auditory canal (AC) are also shown*

<http://www.rad.washington.edu/anatomy/modules/TMJ/TMJMR.html>

## Imaging Modalities for Diagnosis of TMJ Arthritis

- Orthopantomogram (panoramic X-ray)
  - Twilt et al. 2004 [97 JIA – 45% TMJ]
  - Pederson et al. 2001 [169 JCA – 62%]
  - Pearson & Ronning 1996 [71 JCA – 38%]
- CT
  - Ronchezal et al. 1995 [26 JRA – 50%]
  - Wallace et al. 2000 [abstract - 27 JRA – 96% in suspected]



## Imaging Modalities for Diagnosis of TMJ Arthritis - II

---

- Ultrasound
  - Simonini et al. 2003 [abstract – 28 JIA – 63%]
  - Melchiorre et al. 2003 [33 RA and Psoriatic adults – 94% by US vs. 73% by MRI in suspected]
- MRI (any fluid seen in the TMJ is abnormal!)
  - Kuseler et al. 1998 [15 JCA – 87%]
  - Taylor et al. 1993 [15 JRA – 100% in suspected]



## Prevalence of TMJ Arthritis in JIA

---

- Prevalence: [based on X-ray findings in consecutively evaluated patients]
  - 38-62%
  - Historically 42-65% [1964, 1973]
- Incidence:
  - At onset: Unknown
  - Meyer et al. 2000 [abstract – 42 JIA – 57% with clinical diagnosis of TMJ involvement at onset]
  - Newly diagnosed (within 3 years) –  
Kuseler et al. 1998 [15 JCA – 87% by MRI]  
- only children 8 years or older were studied





## Predictors of TMJ Involvement in JIA

---

- Twilt et al. 2004
  - Disease onset at a young age
  - Polyarticular course of disease
  - Extended course of disease
  - Pain during jaw excursion, absence of translation, asymmetry with mouth opening, protrusion, & crepitation

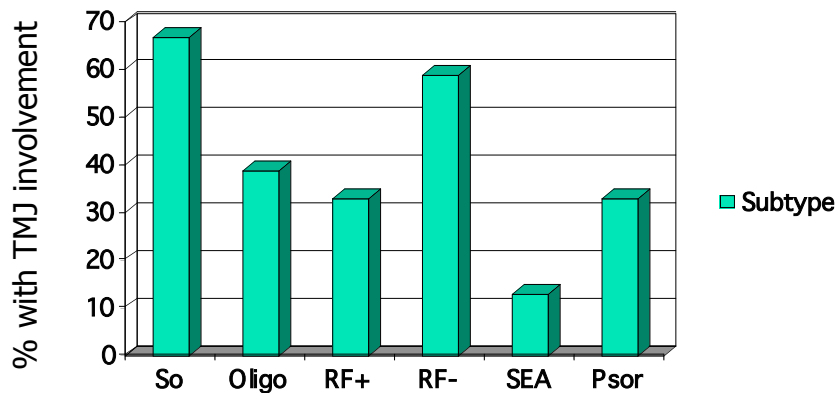


## Predictors of TMJ Involvement in JIA - II

---

- Pederson et al. 2001
  - Disease onset at a young age
  - Polyarticular course of disease
  - ANA(+)
  
  - HLA-B27(+) = LOWER RISK

## JIA Subtype & Frequency of TMJ Arthritis



Twilt et al. J. Rheumatol. 2004;31:1418.

## Unilateral vs. Bilateral TMJ Disease in JIA

- Wallace et al. 2000 (n=26)
  - 46% - bilateral involvement
- Ince et al. 2000 (n=28)
  - 76% - bilateral involvement
- Twilt et al. 2004 (n=44)
  - 50% - bilateral involvement
- Pederson et al. 2001 (n=105)
  - 60% - bilateral involvement

## Extent of TMJ Arthritis in Childhood

- Estimated 50,000 children with JIA in USA
- TMJ arthritis prevalence of ~50%
- About one-half of the children have bilateral involvement
  - $50,000 \div 2 \times 1.5 = \sim 37,500$  arthritic TMJs in kids





## **Morbidity with TMJ Arthritis in JIA**

---

- TMJ Pain
- Local morning stiffness
- Impaired function (chewing, speaking)
- Pain with chewing
- Decreased mouth opening
- Earache
- Cosmetic appearance (micrognathia, facial asymmetry)



## **Increased Morbidity Based on JIA Subtype**

---

- Ince et al. 2000
  - Polyarticular course
  - Early age of onset
  - Disease duration
- Pederson et al. 2001
  - Polyarticular course
  - Early age of onset
- ANA and HLA-B27 – LOWER RISKS



## **Destruction of the Growth Plate**

---

- Growth plate is very superficial, located on the surface of the mandibular condyle head
- Arthritis leads to micrognathia
- Costochondral graft surgery



## **Treatment of Temporomandibular Joint Disorders - I**

---

- **Medications**

- Muscle relaxants if their symptoms are related to muscle tension
- NSAIDs for minor discomfort
- If the TMJ is related to rheumatoid arthritis:
  - corticosteroids
  - methotrexate
  - gold sodium

[<http://www.arthritis-symptom.com/s-z/temporomandibular-joint-disorders.htm>]



## Treatment of Temporomandibular Joint Disorders - II

---

- **Physical therapy & mechanical devices**

- Bruxism is usually treated with splints.
- Splints can be used to treat some cases of internal derangement by holding the jaw forward and keeping the disc in place until the ligaments tighten. The splint is adjusted over 2-4 months.
- TMJ can be treated with ultrasound, electromyographic biofeedback, stretching exercises, transcutaneous electrical nerve stimulation, stress management techniques, or friction massage.

[<http://www.arthritis-symptom.com/s-z/temporomandibular-joint-disorders.htm>]



## Treatment of Temporomandibular Joint Disorders - III

---

- **Surgery**

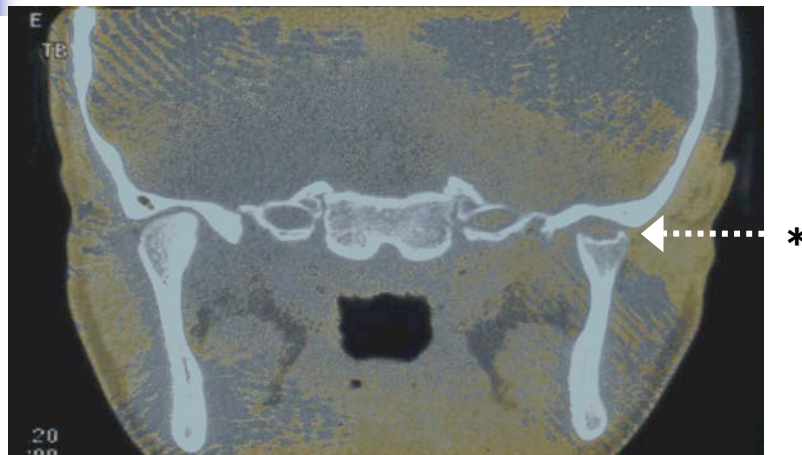- Surgery is ordinarily used only to treat TMJ caused by birth deformities or certain forms of internal derangement caused by misshapen discs.

[<http://www.arthritis-symptom.com/s-z/temporomandibular-joint-disorders.htm>]

## Surgery for the TMJ

- There are five general surgical procedures:
  - disc repair,
  - menisectomy,
  - menisectomy with implant,
  - bone reduction procedures, and
  - arthroscopy.

## AVOID THIS!



Courtesy of David D. Sherry, MD



## **Methotrexate for TMJ Arthritis in JIA**

- Ince et al. Am. J. Dentofacial Orthop. 2000;118:75
  - 45 patients with JRA (63% TMJ involvement by radiographs)
  - Poly JRA on MTX showed less severe TMJ involvement than Poly JRA without MTX



## **Corticosteroid Injections of TMJs are Harmful?**

- "A cortisone-wrecked and bony ankylosed temporomandibular joint."
  - Plast Reconstr Surg. 1989;83:1084
- Temporomandibular joint osteoarthritis. Histopathological study of the effects of intra-articular injection of triamcinolone acetonide.
  - Intra-articular injection of steroid into human osteoarthritic temporomandibular joints acts as a lytic agent (n=44).
  - Haddad. Saudi Med J. 2000 Jul;21(7):675-9.





## **Corticosteroids are NOT Evil! (for inflammatory TMJ disease)**

---

- Vallon et al. Long-term follow-up of intra-articular injections into the temporomandibular joint in patients with rheumatoid arthritis. Swed. Dent. J. 2002;26:149
  - 12 year follow up of 21 adult RA patients following corticosteroid injections (n=11) of TMJs
  - long-term progression of joint destruction was low for both steroid and non-steroid agents



## **Intraarticular Corticosteroids are Used to Treat Other Joints in JIA**

---

- Intraarticular corticosteroid injection in JIA are safe and effective
  - Review – Cleary et al. Arch. Dis. Child. 2003;88:192
- Prevents leg length discrepancy
  - Sherry et al. Arthritis Rheum. 1999;42:2330
- 2<sup>nd</sup> most common therapy to treat pauciarticular juvenile arthritis
  - Cron et al. J. Rheumatol. 1999;26:2036



## **Intraarticular Corticosteroids for TMJ Arthritis in JIA**

---

- Martini et al. J. Rheumatol. 2001;28:1689
  - Case report of arthroscopic synovectomy followed by IA triamcinalone hexacetonide (10 mg) in 15 yo girl with JIA
  - Decreased pain, increased function and mouth opening



## **Retrospective Treatment Study**

---

- To analyze the effect of CT-guided corticosteroid injection of the TMJ joint(s) in children with JIA
  - Retrospective chart review of clinical data (tooth-to-tooth gap, pain)
  - Blinded analysis of pre- and post-injection MRI images of TMJs by a single, experienced pediatric neuroradiologist
  - Prospective patient satisfaction survey by phone call (IRB approved)



## Inclusion Criteria

---

- Meet criteria for definition of JIA
- Evidence of TMJ arthritis by MRI
- Screened by MRI when history (pain with jaw movement), physical exam (foreshortened jaw or deviation with opening), or outside studies (radiographic evidence) suggest TMJ arthritis



## Clinical Suspicion

---

- 18 patients screened by MRI – 17 (94%) found to have arthritis by MRI
- Similarly
  - Wallace et al. screened 27 children with chronic arthritis by CT and found 26 (96%) with TMJ abnormalities
  - J. Rheum. 2000;27 (suppl 58):69



## Demographics

---

- 17 children with JIA and TMJ arthritis
- 11 with polyarticular disease (one RF+)
- 4 with pauciarticular disease
- 1 with systemic-onset disease
- 1 with psoriatic arthritis
- 13/17 were ANA+
- none tested were HLA-B27+



## Demographics - II

---

- Ages at injections (3-16 years)
- Lengths of disease (4 months-7 years)
- 16 girls:one boy
- Ethnicity:
  - 13 Caucasian
  - 2 Hispanic-American
  - 2 African-American



## Concomitant Therapy

---

- 12/17 NSAIDs
- 9/17 weekly methotrexate
- 2/17 TNF inhibitors
- 0/17 steroids, hydroxychloroquine, sulfasalazine



## TMJ Involvement Clinically

---

- Bilateral – 12 (71%)
- Left side only – 3
- Right side only – 2
- 11/17 with TMJ pain
- 14/17 with lateral jaw deviation on mouth opening
- Mean tooth-to-tooth gap of  $3.82 \pm 0.34$  cm (range of 2.7 to 4.7 cm)
  - Normal (4.3 to 5.3 cm)



## MRI Scoring Scheme

- **Grade 1** (normal): No findings characteristic of TMJ arthropathy
- **Grade 2** (acute): Joint effusion, synovial thickening, or marrow edema
- **Grade 3** (subacute): Juxta-articular erosions
- **Grade 3a**: Acute on subacute findings
- **Grade 4** (chronic): Morphologic change or sclerosis of the condyle, abnormal deviation of the meniscus, or loss of articular cartilage
- **Grade 4a**: Acute on chronic findings
- **Grade 5** (end-stage): Ankylosis of the TMJ

Cahill et al. AJR Am. J. Roentgenol., in press.



## Pre-Injection MRI Findings

- TMJ effusions in 17/17 patients
- Bony erosions in 14/17
- Condylar flattening 14/17
- Disc changes 7/17
- All scores of 3a or 4a for TMJs



## Sedation for Treatment

---

- Deep intravenous sedation (in combination)
  - 1-3  $\mu\text{g}/\text{kg}$  fentanyl citrate
  - 2-5 mg/kg pentobarbital sodium
  - 0.1-0.3 mg/kg midazolam hydrochloride
- Continuous cardio-respiratory monitoring
  - Cahill et al. AJR Am. J. Roentgenol., in press.

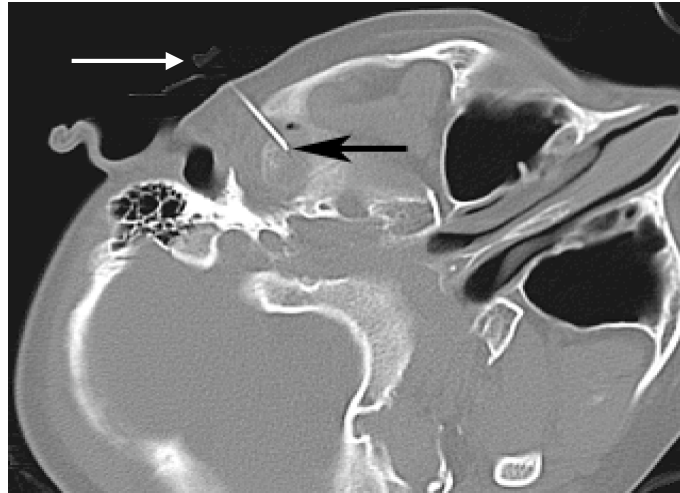


## Therapeutic Approach

---

- Performed by experienced pediatric interventional radiologists
- Child placed supine in CT scanner with head rotated 45° away from TMJ to be injected
- Axial CT imaging in area of interest
- Sterile preparation of access site anterior to tragus
- Local anesthesia with bicarbonate buffered 1% lidocaine (30 gauge needle)
- CT confirmation of needle placement in mandibular fossa
- Injection of triamcinalone acetonide (1cc = 40 mg) into TMJ with 18 or 21 gauge needle
  - Cahill et al. AJR Am. J. Roentgenol., in press.

## CT Guidance

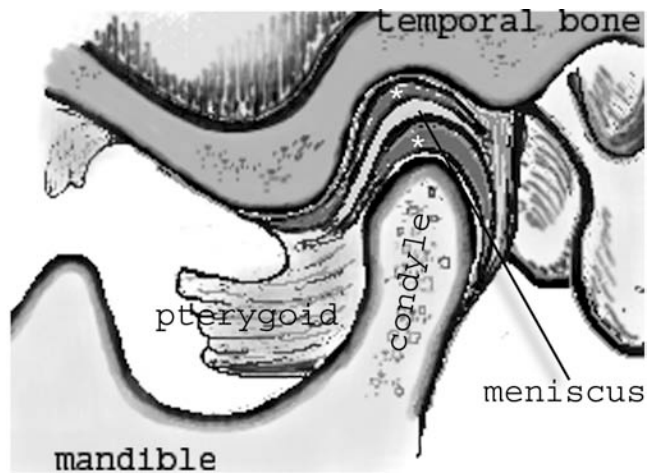


## Data Collection

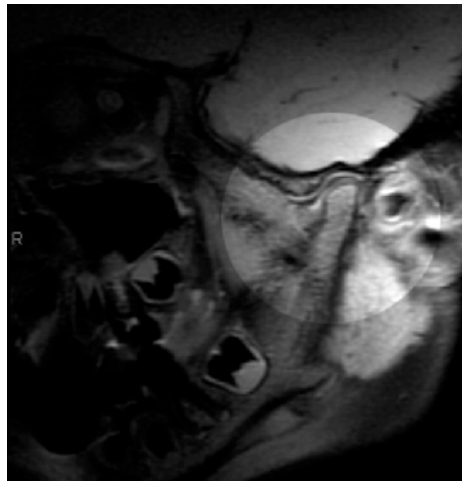
- Tooth-to-tooth gap measurements
- Pain assessment
- MRI findings
  - Effusions
  - Erosions
  - Condylar flattening
  - Disc changes
- Side effects



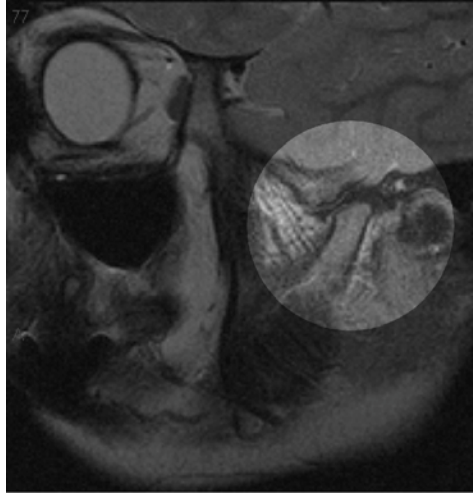
## TMJ Anatomy



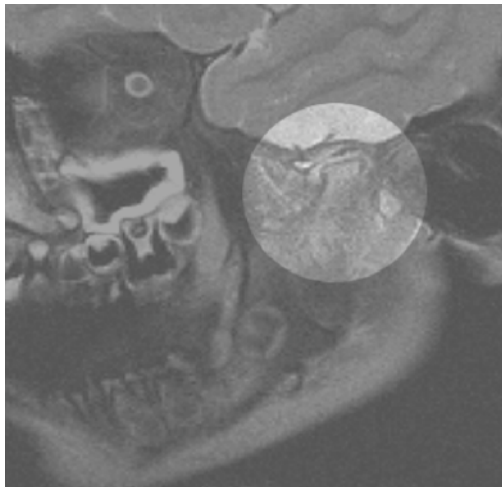
## TMJ Prior to Injection



## TMJ Post-injection Improved



## TMJ Post-injection Persistent Effusion





## Retrospective Study Results

---

- 11/17 with pain prior to injections (only 2 with pain following injections)
- Average increase in tooth-to-tooth gap for 14 patients (3 not measured) of  $0.51 \pm 0.26$  cm
- 13/17 with available follow-up MRI (6-12 months following injections)
  - 11/13 absent or decreased effusions
  - 2/13 increased effusions (both re-injected)
  - No increases in MRI scores following injections



## Complications/Side Effects

---

- Accidental injection of 1cc of ethanol prior to injection of corticosteroids
- Increase in TMJ pain following injection (n=2)
- No infections, subcutaneous atrophy, or hypopigmentation at injection sites
  
- Cushingoid features in one child injected by oromaxillofacial surgery (prior to this study)



## **Summary of Retrospective Study**

---

- CT-guided corticosteroid injection of the TMJ in children with JIA appears safe
- Corticosteroid injection of TMJ arthritis in children with JIA is associated with decreased TMJ pain, increased mouth opening, and decreased TMJ effusions as detected by MRI
- +ANA and polyarticular disease may be risk factors for TMJ arthritis



## **Prospective Study of TMJ Arthritis in JIA**

---

- Determine the incidence of TMJ arthritis at disease onset in children with JIA using MRI and ultrasound
  - Subaim: comparative study of MRI versus ultrasound for diagnosing TMJ arthritis
- Development of a screening protocol to predict those children with JIA at greatest risk for developing TMJ arthritis
  - Using demographics, serologies, physical examination, CHAQ, and questionnaire on TMJ functionality/pain



## Study Timeline

---

### Year 1:

- Recruitment of 60 newly diagnosed JIA subjects (20 paucis, 20 polys, and 20 SEA syndrome controls)
- Measurement of mouth opening
- Questionnaire on TMJ functionality and CHAQ
- Evaluation of baseline labs/serologies
- Completion of TMJ MRI and ultrasound within 8 weeks of diagnosis.

### Year 2:

- Re-evaluation of JIA subjects without TMJ arthritis
- Repeat clinical and subjective assessment as above



## Future Goal (Treatment Trial)

---

- Evaluation of weekly subcutaneous methotrexate, randomized with or without TMJ corticosteroid injection, for the treatment of TMJ arthritis in children with JIA.



## Funding

---

**Nickolett Family Awards  
Program for JRA Research**



**Ethel Brown Foerderer  
Fund for Excellence**



## Credit Where Credit is Due

---

**CHOP Rheumatology**

**Bita Arabshahi**

**Esi DeWitt**

**Sandy Burnham**

**David Sherry**

**CHOP Radiology**

**Anne Marie Cahill**

**Robin Kaye**

**Marissa Bilaniuk**

**Kevin Baskin**

# In Memory of Dr. Frida Gudmundsdottir



## Bibliography

- Aggarwal, S. and Kumar, A. (1989) A cortisone-wrecked and bony ankylosed temporomandibular joint. *Plast Reconstr Surg*, **83**, 1084-1085.
- Cleary, A.G., Murphy, H.D. and Davidson, J.E. (2003) Intra-articular corticosteroid injections in juvenile idiopathic arthritis. *Arch Dis Child*, **88**, 192-196.
- Cron, R.Q., Sharma, S. and Sherry, D.D. (1999) Current treatment by United States and Canadian pediatric rheumatologists. *J Rheumatol*, **26**, 2036-2038.
- Haddad, I.K. (2000) Temporomandibular joint osteoarthritis. Histopathological study of the effects of intra-articular injection of triamcinolone acetonide. *Saudi Med J*, **21**, 675-679.
- Ince, D.O., Ince, A. and Moore, T.L. (2000) Effect of methotrexate on the temporomandibular joint and facial morphology in juvenile rheumatoid arthritis patients. *Am J Orthod Dentofacial Orthop*, **118**, 75-83.
- Kuseler, A., Pedersen, T.K., Herlin, T. and Gelineck, J. (1998) Contrast enhanced magnetic resonance imaging as a method to diagnose early inflammatory changes in the temporomandibular joint in children with juvenile chronic arthritis. *J Rheumatol*, **25**, 1406-1412.



## Bibliography - II

Martini, G., Bacciliero, U., Tregnaghi, A., Montesco, M.C. and Zulian, F. (2001) Isolated temporomandibular synovitis as unique presentation of juvenile idiopathic arthritis. *J Rheumatol*, 28, 1689-1692.

Melchiorre, D., Calderazzi, A., Maddali Bonghi, S., Cristofani, R., Bazzichi, L., Eligi, C., Maresca, M. and Ciompi, M. (2003) A comparison of ultrasonography and magnetic resonance imaging in the evaluation of temporomandibular joint involvement in rheumatoid arthritis and psoriatic arthritis. *Rheumatology (Oxford)*, 42, 673-676.

Meyer, k., Foeldvari, I., Huck, I., Haubrich, S. and Kahl-Nieke, B. (2000) Dentofacial morphology and temporomandibular (TMJ) aspects in children with juvenile idiopathic arthritis (JIA) (abstract). *Arthritis Rheum*, 43 (suppl 9), S120.

Pearson, M.H. and Ronning, O. (1996) Lesions of the mandibular condyle in juvenile chronic arthritis. *Br J Orthod*, 23, 49-56.



## Bibliography - III

Pedersen, T.K., Jensen, J.J., Melsen, B. and Herlin, T. (2001) Resorption of the temporomandibular condylar bone according to subtypes of juvenile chronic arthritis. *J Rheumatol*, 28, 2109-2115.

Ronchezel, M.V., Hilario, M.O., Goldenberg, J., Lederman, H.M., Faltin, K., Jr., de Azevedo, M.F. and Naspitz, C.K. (1995) Temporomandibular joint and mandibular growth alterations in patients with juvenile rheumatoid arthritis. *J Rheumatol*, 22, 1956-1961.

Sherry, D.D., Stein, L.D., Reed, A.M., Schanberg, L.E. and Kredich, D.W. (1999) Prevention of leg length discrepancy in young children with pauciarticular juvenile rheumatoid arthritis by treatment with intraarticular steroids. *Arthritis Rheum*, 42, 2330-2334.

Simonini, G., Melchiorre, D., Vierucci, S., Giani, T., Cimaz, R. and Falcini, F. (2003) Ultrasound assessment of temporomandibular joint involvement in a cohort of juvenile idiopathic arthritis children (abstract). *Arthritis Rheum*, 48 (suppl 9), S96.





## Bibliography - IV

---

Taylor, D.B., Babyn, P., Blaser, S., Smith, S., Shore, A., Silverman, E.D., Chuang, S. and Laxer, R.M. (1993) MR evaluation of the temporomandibular joint in juvenile rheumatoid arthritis. *J Comput Assist Tomogr*, 17, 449-454.

Twilt, M., Mobers, S.M., Arends, L.R., ten Cate, R. and van Suijlekom-Smit, L. (2004) Temporomandibular involvement in juvenile idiopathic arthritis. *J Rheumatol*, 31, 1418-1422.

Vallon, D., Akerman, S., Nilner, M. and Petersson, A. (2002) Long-term follow-up of intra-articular injections into the temporomandibular joint in patients with rheumatoid arthritis. *Swed Dent J*, 26, 149-158.

Wallace, C.A., Sherry, D.D. and Kahn, S.J. (2000) Computerized tomography (CT) for evaluation of temporal mandibular joints (TMJ) in childhood arthritis (abstract). *J Rheumatol*, 27 (suppl 58), 69.